



**PATIENT PRESENTING CLINICAL SIGNS**

Beau Mccue Grade 3/6 murmur, considering dental.

**ULTRASONOGRAPHIC EXAMINATION OF THE HEART**

**SPECIES**

Canine

**BREED**

Labradoodle

**SEX**

MN

**AGE**

9yr

**WEIGHT**

42lb

CANINE CARDIAC PARAMETERS	MR VMAX (m/s)	TR VMAX (m/s)	LA/AO M-mode	LA/AO (Heart Base; Swe)	FS (%)	EF (%)	EPSS (cm)
NORMAL PARAMETER	4.5-5.5	<2.7	1.3	Up to 1.6	28-40	40-100	<0.6
PATIENT	6.0	3.6	1.5	1.8	20	39	0.1
CANINE CARDIAC PARAMETERS	HR (BPM)	AV VMAX (m/s)	PV MAX (m/s)	BODY WEIGHT	LAD LA MAX 4 Chamber	LVIDd Avg; 2D and m-mode short axis (cm)	LVIDs Avg; 2D and m-mode short axis (cm)
NORMAL PARAMETER	50-100	0.7-1.7	0.7-1.6				
PATIENT	135	210	100	42lb	5.1	4.68	--

**Cardiac Presentation**

Mitral and tricuspid insufficiency noted in this patient. Tricuspid insufficiency velocity is that of mild to moderate pulmonary hypertension. Volume overload noted in the left atrium, left ventricle with subnormal contractility is non-compensatory. Prolapsed anterior mitral valve leaflet noted. Aortic and pulmonic outflow velocities were adequate. No pericardial or pleural effusion. Complete filling of the left atrium noted on color flow assessment. The mitral valve hepatic veins were not dilated. No evidence of right-sided heart failure.

**ULTRASONOGRAPHIC FINDINGS**

- Stage B2+ valvular disease

**INTERPRETATION OF THE FINDINGS & FURTHER RECOMMENDATIONS**

There is significant aesthetic risk in this patient. Recommend initiating Pimobendan 0.3 mg/kg BID, ACE inhibitor ½ mg/kg SID and spironolactone 1-2 mg/kg SID. Recheck echo in 2 to 3 weeks to assess for safety for dental procedure.

**INTERPRETED BY**

Eric Lindquist, DMV DABVP, Cert. IVUSS

**IMAGING PERFORMED BY**

Kerri Becker

**HOSPITAL NAME**

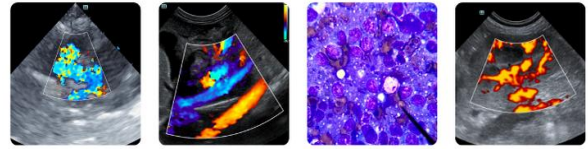
Wyckoff Veterinary Hospital

**REFERRING VET**

Dr Eisenberg

**INVOICE**  
24731

**DATE**  
05/06/2026



**PATIENT**  
 Beau Mccue

**SPECIES**  
 Canine

**BREED**  
 Labradoodle

**SEX**  
 MN

**AGE**  
 9yr

**WEIGHT**  
 42lb

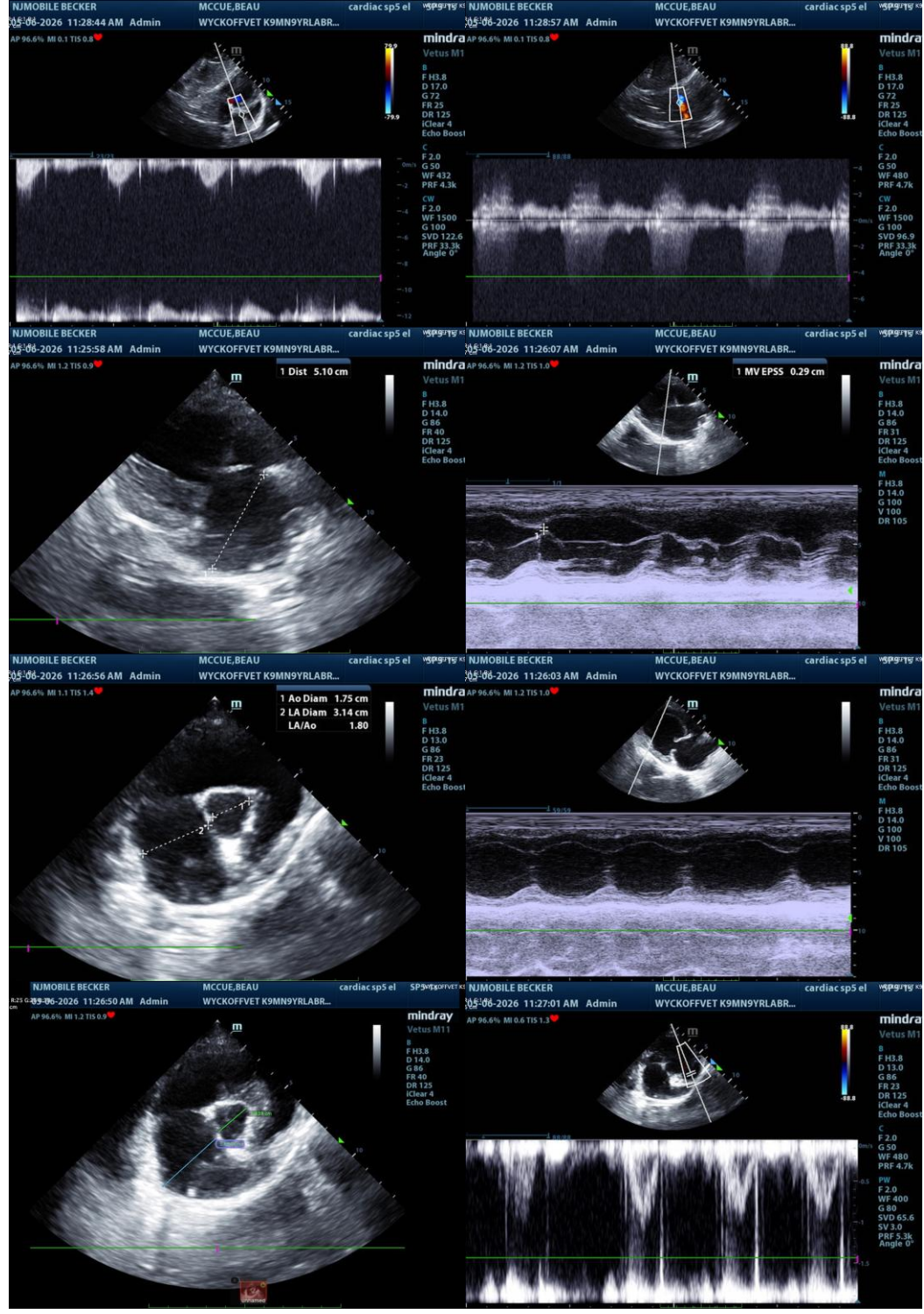
**INTERPRETED BY**  
 Eric Lindquist, DMV  
 DABVP, Cert. IVUSS

**IMAGING PERFORMED BY**  
 Kerri Becker

**HOSPITAL NAME**  
 Wyckoff Veterinary  
 Hospital

**REFERRING VET**  
 Dr Eisenberg

**INVOICE**  
 24731



**DATE**  
 05/06/2026



**PATIENT**

Beau Mccue

The information and recommendations provided are based on the images presented by the referring veterinarian/sonographer. No evaluation can be communicated regarding pathology that was not visible in the image/video clips provided.

**SPECIES**

Canine

Thank you for this referral. If the clinical or image interpretation does not parallel your findings or if I can be of any further assistance, please contact me.

**BREED**

Labradoodle

**Eric Lindquist**, DMV, DABVP, Cert. IVUSS, CEO of SonoPath.com  
info@SonoPath.com

**SEX**

MN

**AGE**

9yr

**WEIGHT**

42lb

**INTERPRETED BY**

Eric Lindquist, DMV  
DABVP, Cert. IVUSS

**IMAGING  
PERFORMED BY**

Kerri Becker

**HOSPITAL NAME**

Wyckoff Veterinary  
Hospital

**REFERRING VET**

Dr Eisenberg

**INVOICE**

24731

**DATE**

05/06/2026